

Leishmaniasis in North Central Province, Sri Lanka –Epidemiology and Therapeutic Response

Ranawaka RR¹, Consultant Dermatologist, Teaching Hospital Anuradhapura

Weerakoon HS², Medical Officer Dermatology Unit, Teaching Hospital Anuradhapura

Opathella N³, Medical Officer Dermatology Unit, Teaching Hospital Anuradhapura

Subasinha C⁴, Medical Officer Dermatology Unit, Teaching Hospital

Abstract

We analyzed 404 (401 cutaneous, 2 mucocutaneous and 1 visceral) leishmania patients for epidemiology, geographical distribution, periodicity and treatment response over 2.5 years from June 2007 to December 2009. Three (0.8%) patients, developed leishmaniasis recidivans, and 4 (0.4%) recurred within 13 months.

Introduction

Cutaneous leishmaniasis (CL) is growing a public health problem in several parts of the world, including Sri Lanka.¹⁻³ The causative organism was identified as *Leishmania donovani* zymodeme MON-37.⁴ DNA sequencing and microsatellite analyses showed that these parasites are closely related to those causing visceral leishmaniasis in the Indian subcontinent.⁵ The first case of locally acquired leishmaniasis was documented in 1992.⁶ The first case of mucocutaneous^{7,8} and visceral⁹ leishmaniasis was reported from Anuradhapura district in 2005 and 2007 respectively. Today more than 500 patients are reported annually from Anuradhapura, Polonnaruwa, Matara, Thangalle and Hambanthota districts.

WHO recommended intralesionally administered pentavalent antimony compounds; sodium stibogluconate¹⁰⁻¹³ and liquid nitrogen cryotherapy¹⁴⁻¹⁷ are the widely used therapy in Sri Lanka. Ranawaka RR et al (2009)¹⁸ proved that intralesionally administered 7% hypertonic sodium chloride was effective against *L. donovani* CL which agreed with published data by Sharquie KE et al (1995, 1997).^{19,20}

This study analyzed the epidemiology and the treatment response of patients with leishmaniasis in North Central Province over 2.5 years (June 2007 to December 2009) in North Central province Sri Lanka.

Material and Methods

Majority of patients in this study were from Anuradhapura district, which is the largest district in the country with low population density of 112 persons per sq km. The majority was rural population (92.7%) engaged in farming, while 7.1% urban and 0.1% estate according to the Department of Census and Statistics, 2001 (www.statistics.gov.lk/PopHouSat/PDF/Population/p9p8%20Ethnicity.pdf).

Slit-skin-smear test (SSS) was performed as a routine. In negative SSS, if clinically indicative, skin biopsy was performed. Polymerase chain reaction (PCR) and culture were not done routinely. Patients were treated with either sodium stibogluconate (SSG), intralesional hypertonic saline (HS) or liquid nitrogen cryotherapy (LN).

Results

There was 404; 401 cutaneous leishmaniasis with 607 skin lesions, 2 mucocutaneous and 1 visceral leishmaniasis.

267 men and 134 women with M: F ratio of 1.9:1 was studied (table). Average age of our population was 32 years (ranged 13 months to 80 years). Except one Sri Lankan Moor all the patients were Sinhalese. Except one man who had acquired the disease while he is in Dubai, all others were autochthonous.

48% were from Thalawa (10km) and Padaviya (90km to our centre) Medical Officer of Health (MOH) areas (figure 1). 79.4 % were civilians who had acquired the disease from the locality. 20.5% were military personnel who had acquired the disease while they were working in Northern and Eastern provinces; Welioya (Padaviya MOH) (55), Mulathiw (4), Tricomalee (3), Jaffna (3), Vavniya (3), Kilinochchiya (2), Toppigala (2), Mannar (2) and Ampara (1).

Average delay in presentation was 9 months (ranged 4 weeks to 5 years) (figure 2). The mean number of patients' presentation for a given month during the period of study was 6, 10.3 and 18.8 in 2007, 2008 and 2009 respectively (figure 3).

91% of lesions were located on exposed areas of the body. 11 (4.5%) had at least one other family member affected. 14.3% had associated photodermatitis which disappeared when CL healed. 43.7% of cutaneous lesions had hypopigmented halo around.

Mucocutaneous leishmaniasis

41-year-old male farmer from Eppawala (Thalawa MOH) with a non-healing ulcer on lower lip was extensively investigated for a granulomatous mid line lesion since 2001.⁸ His SSS done in 2006 and 2007 were negative, and repeated in October 2008 was positive, and confirmed with positive PCR and culture. Due to delayed diagnosis he was left with total destruction of nasal septum, phintrum and lower lip.

The second patient, 55-year-old postmaster from Rambewa MOH (15km) presented with a non-healing ulcer on left buccal mucosa for 6 months duration. He was diagnosed with tissue biopsy showing numerous amastigotes.

Visceral leishmaniasis

45-year-old male farmer who is a heavy alcoholic from Thabuththegama MOH (15km) was extensively investigated for pancytopenia, hepatosplenomegaly with massive spleen in medical unit since 2007. He defaulted follow-up in 2008 when he was informed liver biopsy, and readmitted in 2009 with worsening of symptoms. He died following liver biopsy and visceral leishmaniasis was diagnosed seeing Kupffer cells filled with amastigotes. In post mortem specimens spleen and liver were infiltrated with numerous amastigotes.

Treatment response

87 (136 lesions) and 67 (93 lesions) patients were treated with SSG and HS respectively in a study conducted by Ranawaka RR et al.¹⁸ SSG showed 100% cure within 1-6 injections (mean 3.24); while HS, 92.2% cure within 1-10 injections (mean 5.27). Except for post inflammatory hyperpigmentation which faded-out over 6-8 months there were no systemic or local side effects with either SSG or HS. Two (0.8%) patients, whom were treated with SSG, and one treated with hypertonic saline developed leishmaniasis recidivans. One (0.4%) patient who was initially treated with SSG recurred after 13 months.

65 patients (121 lesions) were treated with LN; showed 91.7% cure rate within 1-7 cryosessions (mean 3.57). Pain which last 15-30 minutes, ulceration (33%), post inflammatory hypopigmentation (46.9%), and visible scar (43%), were the drawbacks in LN; three (4.6%) patients recurred within 6 months of cure.¹⁶

Discussion

Young men of 16-45 age groups were the mostly infected. Majority (79.4%) were civilians, in contrast to the observation in 2003⁴ where most of them were military personnel.

In Anuradhapura district 90.7% was Sinhalese, followed by 8.3% Sri Lankan Moors and 0.7% SL Tamils. In this study group except one SL Moor all the infected patients were Sinhalese. The difference in clothing, cultural and social behavior may partly explain our observation.

Although majority of our patients lived in moderately built brick houses with 5-6 members in one family, only 11 (7 families) had multiple family members infected. These patients, who had intra-familial infection, did not show higher incidence of multiple lesions or severe disease.²¹ Why some individuals are more prone to get infection than other members of the family, to be further studied.

In North Central Province 48% of the patients were from Thalawa and Padaviya MOH. From Welioya (Padaviya MOH) high number of military personnel still present as reported in 2003.⁴

Belli A et al²² described hypopigmented halo around the lesion in atypical CL due to *L. chagasi*, which was also noted on 13.9- 44% Sri Lankan patients.^{2,3} This was an important differentiating feature, noted in 43.7% of CL lesions in this study group, which was marked on dark skinned individuals. These lesions have misdiagnosed clinically and histopathologically as tuberculoid leprosy, since both diseases show granulomatous pathology.

Seasonal pattern with monsoonal rainy periods (November- January) was not noted in North Central Province (figure 3). But in 2008 and 2009 there was marked increase in patient presentation to the clinic following awareness programs. But still there is an average of 9 months delay.

The first visceral leishmaniasis in Sri Lanka was diagnosed by liver biopsy showing amastigotes within Kupffer cells.⁹ If not vigilant there is a possibility to under diagnose visceral leishmaniasis, and end up in fatality as in our patient. Patients with high suspicious of visceral and mucocutaneous leishmaniasis should undergo PCR and culture.

The natural healing time reported on *L. major* CL was 9 months or more and *L. tropica* was 1 year or more.²³ Natural healing time for *L. donovani* CL is not studied yet. But from this study we observed that 23.6 % of lesions lasted for more than 11 months. Therefore natural healing time in *L. donovani* CL can probably take 12 months or more.

In Sri Lanka only method of disease control is the early identification of patients and early treatment. We used three modes of treatments where none of them showed systemic side effects. Most effective therapy was SSG. Disadvantage in SSG was its high cost, possible systemic side effects and interrupted supply.

HS was effective although average number of injections required per lesion was higher.¹⁸ HS was cheap (US\$ <1 per 500ml) compared to SSG (US\$ 150 per 100ml), no systemic side effects and could easily be made locally at all centers. There was no significant association between the rapidity of clinical response and the size, the duration and the location of the lesions.¹⁸

Many centers in Sri Lanka use LN as the first line of treatment in spite of local side effects. Authors recommend to avoid LN on face, areas of cosmetically concerned and the lesions >2cm. We recommend giving cryotherapy fortnightly (not weekly); and to use cryoguns (instead of cotton swabs attached to eakles); which may minimize ulceration, and therefore scarring.¹⁶

Disadvantage in all 3 therapies were that these were painful procedures, needed several hospital visits and professionally trained medical staff. Ideal therapy to control an infectious disease should be cheap, less toxic, orally or topically administered drug which can be issued by field medical staff such as public health inspectors and public health midwives.

Most number of patients was reported from Padaviya and Padavi Sripura, which are situated 90km and 120km respectively from Teaching Hospital Anuradhapura, the nearest tertiary care centre. Due to long distance and traveling difficulty infected patients are reluctant to seek treatment. We must train medical officers and more importantly Medical Lab Technicians in these endemic areas to diagnose and treat patients. A trained Medical Lab Technician should confine to leishmania investigations at least in high endemic areas to avoid false negative results in pauci parasitic specimens.

Vector, reservoir host and disease transmission in Sri Lanka had not been understood yet^{24, 25} and need further studies to be conducted by responsible authorities and implement vector control program as early as possible. From this analysis it is evident that the disease is confined to a few MOH areas in North Central Province. Therefore if start early, disease control by controlling the vector would be easy and will be successful. Unless these actions are implemented urgently spread of this fatal disease is unavoidable in near future.

Acknowledgements: We acknowledge assistance given by Mrs. Prema Ekanayake (nursing officer) in department of dermatology, Teaching Hospital Anuradhapura, during preparation of drugs and treatment of the patients.

Figure legends

Figure 1 – Proportion of subject distribution according to Medical Officer of Health (MOH) areas in Anuradhapura district, Sri Lanka, from July 2007 to June 2009
NPC: Nuwaragampalatha Central, NPE: Nuwaragampalatha East

Figure 2 – Proportion of subjects’ presentation to the skin clinic from the time of first appearance of cutaneous leishmaniasis lesions

Figure 3 - Distribution of the cutaneous leishmaniasis cases according to the month of presentation from January 2007 to November 2009 in Anuradhapura district, Sri Lanka

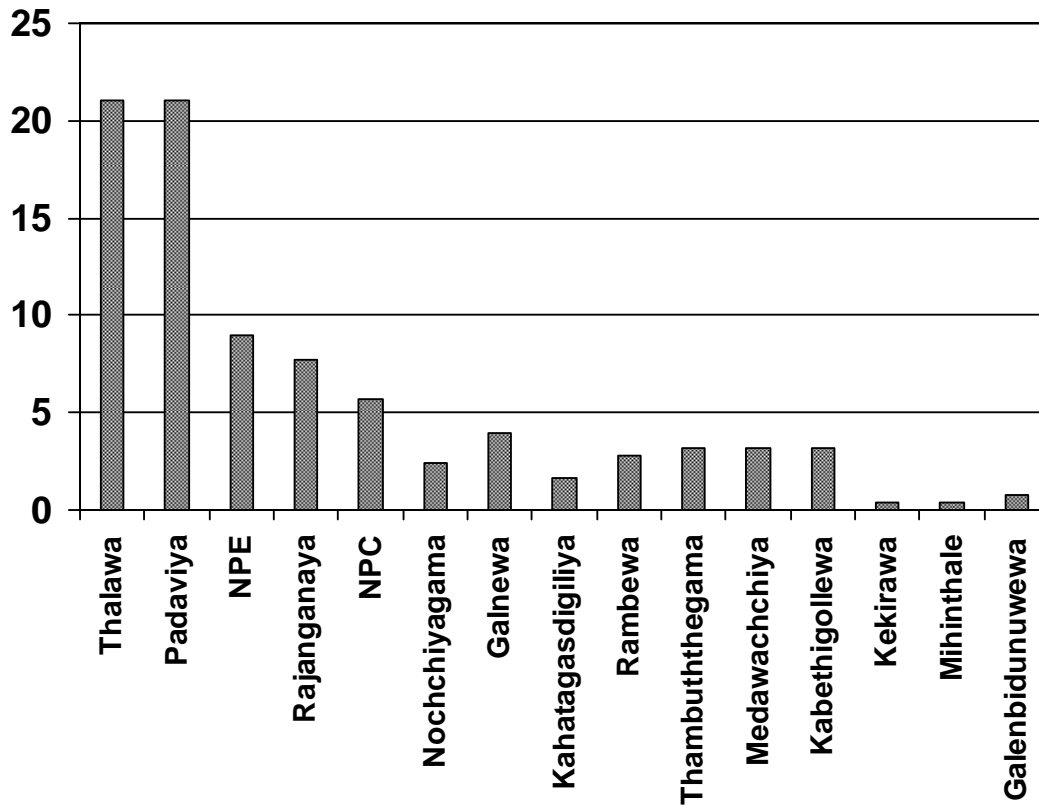


Figure 1 - Proportion of subject distribution according to Medical Officer of Health (MOH) areas in Anuradhapura district, Sri Lanka, from July 2007 to December 2009
 NPC: Nuwaragampalatha Central, NPE: Nuwaragampalatha East

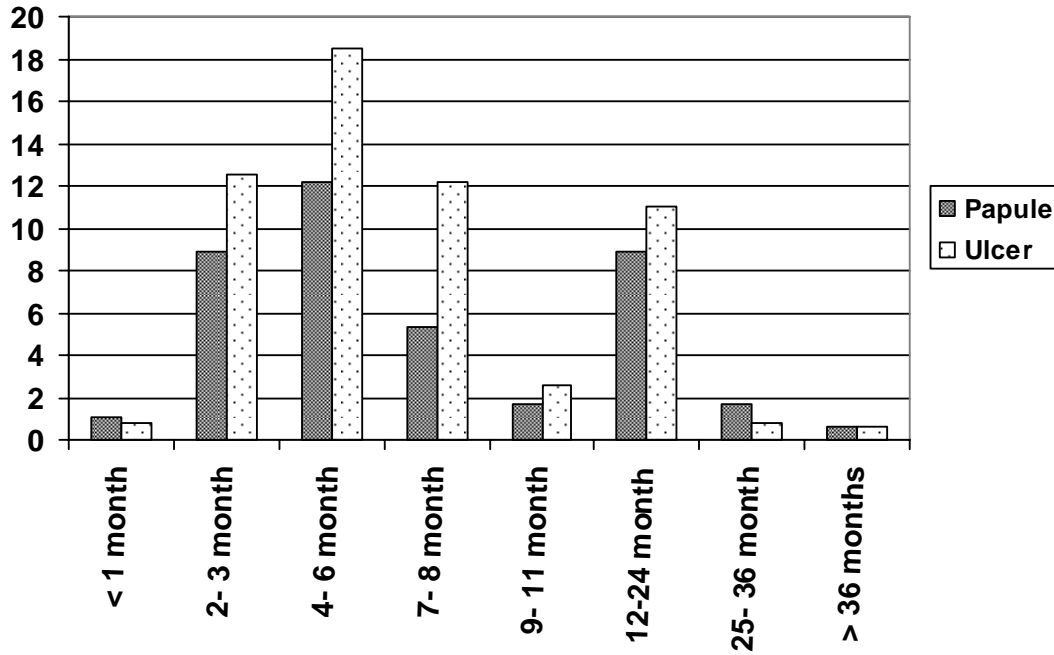


Figure 2 - Proportion of subjects' presentation to the skin clinic from the time of first appearance of cutaneous leishmaniasis lesions

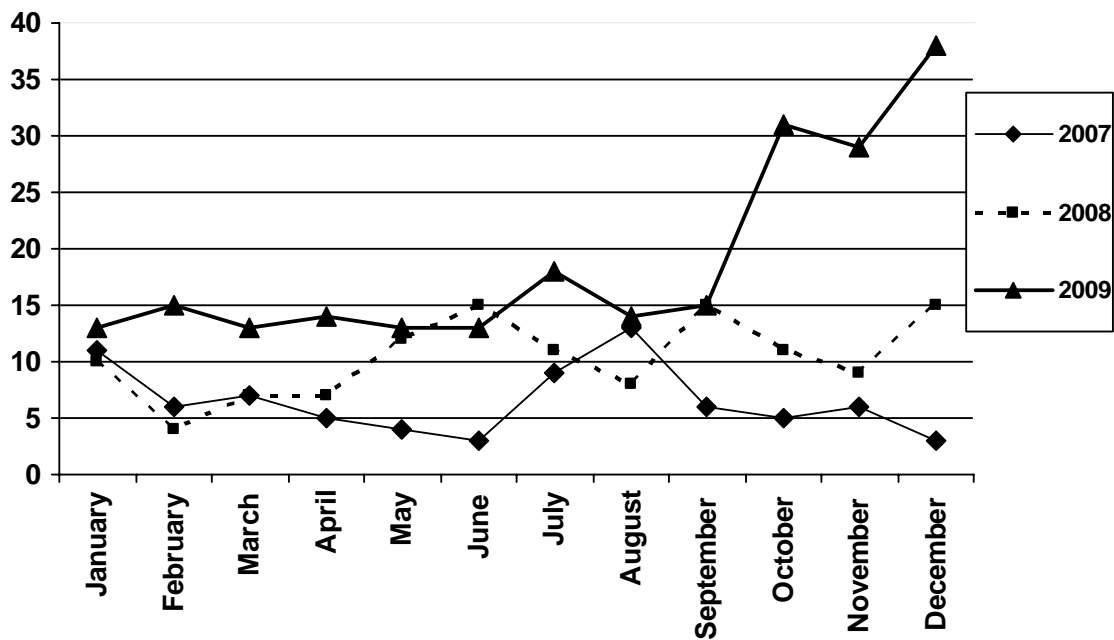


Figure 3 - Distribution of the cutaneous leishmaniasis cases according to the month of presentation from January 2007 to December 2009 in Anuradhapura district, Sri Lanka

Table - Characteristics of the sample by age and sex distribution, occupational distribution, clinical presentation, site and number of cutaneous leishmaniasis lesions*

	Number		Percentage
	Male	Female	
Age and sex distribution			
0-15	23	35	14.3
16-30	112	35	36.3
31-45	78	16	23.2
46-59	43	34	19
>60 years	11	9	5
Occupational distribution			
Farmers	102		25
Military personnel	83		20.5
School children	78		19.3
House wives	32		-
Home guards	24		-
Teachers	10		-
Others	75		-
Clinical presentation			
1. papules (≤ 1 cm diameter)	181		33
2. nodules (> 1 cm diameter)	56		10.2
3. plaques	31		5.6
4. nodulo-ulcerative lesion	271		49.4
5. chronic non healing ulcers with undermined edges without induration	9		1.6
Site of the lesion			
Ear	5		-
Nose	3		-
Lip	8		-
Face	82		15
arm	71		13
Forearm	164		30
Hand	9		-
Fingers	8		-
Thigh	3		-
Knee	3		-
Leg below knee	107		19.5
Feet	3		-
Trunk	54		10
buttock	1		-
Number of lesions			
1	268		66.3
2	77		19
3	21		5
4	7		2
> 4 (5- 11 lesions)	11		2.7

* Totals may vary due to missing data.

References:

1. Castellani A. Leishmania donovani in Ceylon. *J Trop Med*. 1904; **10**: 262-263.
2. Nawaratna SKS, Weilgama DJ, Wijekoon CJ, Dissanayaka M, Rajapaksha K. Cutaneous Leishmaniasis, in Sri Lanka. *Emerg Infect Dis*. 2007; **7**:1068- 1070.
3. Rajapaksa US, Ihalamulla RL, Udagedera C, Karunaweera ND. Cutaneous leishmaniasis in Southern Sri Lanka. *Trans R Soc Trop Med Hyg* 2007; **101**:799-803.
4. Karunaweera ND, Pratlong F, Siriwardane HVYD, Ihalamulla RL, Dedet JP. Sri Lanka Cutaneous leishmaniasis caused by leishmania donovani zymodeme MON-37. *Trans R Soc Trop Med Hyg*. 2003; **97**: 380-381.
5. Siriwardana HVYD, Noyes HA, Beeching NJ, Chance ML, Karunaweera ND, Bates PA. Leishmania donovani and cutaneous leishmaniasis, Sri Lanka. *Emerg Infect Dis*. 2007; (13) **3**: 476- 478.
6. Athkorala DN, Seneviratne JKK, Ihalamulla RL, Premaratne UN. Locally acquired cutaneous leishmaniasis in Sri Lanka. *J Trop Med Hyg*. 1992; **95**: 432- 433.
7. Rajapaksa US, Ihalamulla RL, Karunaweera ND. First report of mucosal tissue localization of leishmaniasis in Sri Lanka. *The Ceylon Medical Journal* 2005 Jun; **50** (2): 90- 91.
8. Rathnayake D, Ranawake RR, Sirimanna G, Siriwardhane Y, Karunaweera N, De Silva R. Co-infection of mucosal leishmaniasis and extra pulmonary tuberculosis in a patient with inherent immune deficiency. *Int J Dermatol*. 2010 May; **49**(5):549-51.
9. Abeygunasekara PH, Costa YJ, Seneviratne N, Ratnatunga N, Wijesundara MS. Locally acquired visceral leishmaniasis in Sri Lanka. *The Ceylon Medical Journal*. 2007; **52**(1): 30-31.
10. Faris RM, Jarallah JS, Khoja TA, al-Yamani MJ. Intralesional treatment of cutaneous leishmaniasis with sodium stibogluconate antimony. *Int J Dermatol*. 1993; **32**(8):610-612.
11. Tallab TM, Bahamdani KA, Mirdad S, Johargi H, Mourad MM, Ibrahim K, Sherbini AH, Karkashan E, Khare AK, Jamal A. Cutaneous leishmaniasis: schedules for intralesional treatment with sodium stibogluconate. *Int J Dermatol*. 1996 Aug; **35**(8): 594- 597.
12. Solomon M, Baum S, Barzilai A, Pavlotsky F, Trau H, Schwartz E. Treatment of cutaneous leishmaniasis with intralesional sodium stibogluconate. *J Eur Acad Dermatol Venereol*. 2009 Oct; **23**(10):1189-92.
13. Herwaldt BL, Berman JD. Recommendations for treating leishmaniasis with sodium stibogluconate (Pentostam) and review of pertinent clinical studies. *Am J Trop Med Hyg*. 1992; **46**(3): 296-306.

14. Memisoglu RH, Kotogyan A, Acar AM, Ozpoyraz M, Uzun S. Cryotherapy in cases with leishmaniasis cutis. *J Eur Acad Dermatol Virology*. 1995;**4**: 9-13.
15. Asilian A, Sadeghinia A, Faghihi G, Momeni A, Amini Harandi A. The efficacy of treatment with intralesional meglumine antimoniate alone, compared with that of cryotherapy combined with the meglumine antimoniate or intralesional sodium stibogluconate, in the treatment of cutaneous leishmaniasis. *Ann Trop Med Parasitol* 2003; **97**(5): 493- 498
16. Ranawaka RR, Weerakoon HS, Opathella N. Liquid Nitrogen Cryotherapy on *L. donovani* Cutaneous Leishmaniasis. *J Dermatolog Treat*. 2010 Sep 6.
17. Mosleh IM, Geith E, Natsheh L, Schonian G, Abotteen N, Kharabsheh S. Efficacy of weekly cryotherapy regimen to treat *Leishmania major* cutaneous leishmaniasis. *J Am Acad Dermatol*. 2008; **58**: 617-24.
18. Ranawaka RR, Weerakoon HS. Randomized, Double Blind, Comparative Clinical Trial on Efficacy and Safety of Intralesional Sodium Stibogluconate and Intralesional 7% Hypertonic Sodium Chloride against Cutaneous Leishmaniasis Caused by *L. donovani*. *J Dermatolog Treat*. 2010 Sep;**21**(5):286-93.
19. Sharquie KE. A new intralesional therapy of cutaneous leishmaniasis with hypertonic sodium chloride solution. *J Dermatol*. 1995; **22**(10): 732- 737.
20. Sharquie KE, Najim RA, Farjou IB. A comparative controlled trial of intralesionally-administered zinc sulphate, hypertonic sodium chloride and pentavalent antimony compound against acute cutaneous leishmaniasis. *Clin Exp Dermatol*. 1997; **22**(4): 169-173.
21. Samaranyake TN, Dissanayake VHW, Fernando SD. Clinical manifestations of cutaneous leishmaniasis in Sri Lanka - possible evidence for genetic susceptibility among the Sinhalese. *Ann Trop Med Parasitol*. 2008; **102**(5): 383- 390.
22. Belli A, Garcia D, Palacios X, Rodriguez B, Valle S, Videa E et al. Widespread atypical cutaneous leishmaniasis caused by *L. chagasi* in Nicaragua. *Am J Trop Med Hyg*. 1999; **61**: 380-385.
23. Griffiths WAD, Croft SL. Cutaneous leishmaniasis. *Postgraduate Doctor Middle East* 1980; **3**: 338-40.
24. Surendran SN, Kajatheepan A, Ramasamy R. Socio-environmental factors and sandfly prevalence in Delft Island, Sri Lanka: implications for leishmaniasis vector control. *J Vector Borne Dis*. 2007; **44**: 65-68.
25. Nawaratna SS, Weilgama DJ, Rajapaksa K. Cutaneous leishmaniasis in Sri Lanka: a study of possible animal reservoirs. *Int J Infect Dis*. 2009 Jul;**13**(4):513-7.