

## Nodular prurigo

M P Kumarasinghe<sup>1</sup>, S P W Kumarasinghe<sup>2</sup>, A Tilakaratna<sup>3</sup>

*Sri Lanka Journal of Dermatology*, 1997, 2, 23

A 53 year old male presented with intensely pruritic, hyperpigmented, excoriated nodules on upper and lower limbs of 3 years duration. The differential diagnosis included nodular prurigo, chronic papular urticaria and hypertrophic lichen planus.

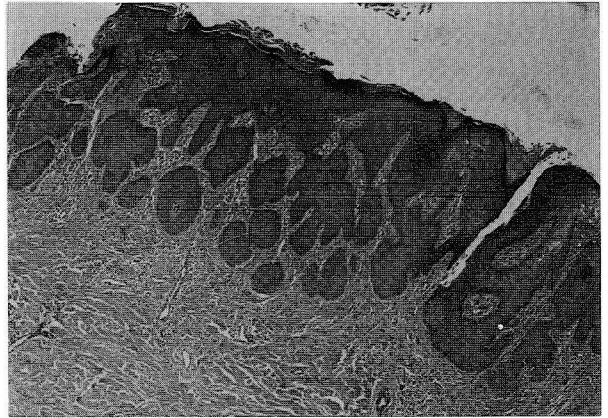
A 4mm punch biopsy was performed on a lesion on the right leg and the specimen was fixed in 10% formol saline.

Light microscopic appearance of the haematoxylin and eosin stained sections showed the following features.

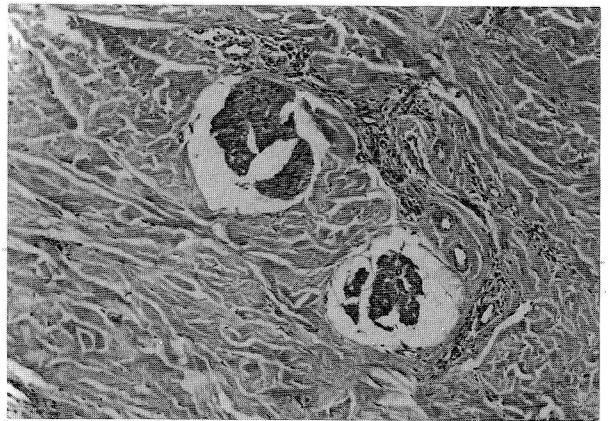
Epidermal changes were hyperkeratosis, acanthosis and papillomatosis with downward proliferation of the epidermis simulating pseudocarcinomatous hyperplasia. There was no hypergranulosis, irregular acanthosis with saw toothing or basal cell degeneration to suggest lichen planus. No intraepidermal inflammation or spongiosis described in chronic papular urticaria were seen.

The dermis showed non specific chronic inflammation and proliferation and hyperplasia of cutaneous nerves. No pigment laden macrophages or eosinophils were seen.

The above histologic features confirmed the diagnosis of nodular prurigo.



**Figure 1.** Downward proliferation of the epidermis simulating pseudocarcinomatous hyperplasia (× 100).



**Figure 2.** Non specific dermal inflammation and proliferation and hyperplasia of cutaneous nerves (× 400).

<sup>1</sup> Associate Professor, Department of Pathology, Faculty of Medicine, Colombo.

<sup>2</sup> Consultant Dermatologist, General Hospital, Kalutara

<sup>3</sup> Lecturer in Pathology, Faculty of Medicine, Kelaniya.